

## PERCUTANEOUS DRAINAGE COMPARED WITH SURGERY FOR HEPATIC HYDATID CYSTS

MOHAMMAD SULTAN KHUROO, D.M., NAZIR A. WANI, M.S., GUL JAVID, M.D., BASHIR A. KHAN, M.D., GHULAM N. YATTOO, M.D., ALTAF H. SHAH, M.D., AND SAMOON G. JEELANI, M.D.

**ABSTRACT**

**Background** In recent years percutaneous drainage has been used successfully to treat the hepatic hydatid cysts of echinococcal disease. We performed a controlled trial to compare the safety and efficacy of percutaneous drainage with those of surgical cystectomy, the traditional treatment.

**Methods** In a prospective study, we randomly assigned 50 patients with hepatic hydatidosis to treatment with percutaneous drainage (25 patients) or cystectomy (25). Albendazole (10 mg per kilogram of body weight per day for eight weeks) was administered to the patients who underwent percutaneous drainage. Serial assessments included clinical and biochemical examinations, ultrasonography, and serologic tests of echinococcal-antibody titers.

**Results** The mean ( $\pm$ SD) hospital stay was  $4.2 \pm 1.5$  days in the drainage group and  $12.7 \pm 6.5$  days in the surgery group ( $P < 0.001$ ). Over a mean follow-up period of 17 months, the mean cyst diameter decreased from  $8.0 \pm 3.0$  to  $1.4 \pm 3.5$  cm ( $P < 0.001$ ) after percutaneous drainage and from  $9.1 \pm 3.0$  to  $0.9 \pm 1.8$  cm ( $P < 0.001$ ) after surgery. The final cyst diameter did not differ significantly between the two groups ( $P = 0.20$ ). The cysts disappeared in 22 patients (88 percent) in the drainage group and in 18 (72 percent) in the surgery group ( $P = 0.29$ ). After an initial rise, the echinococcal-antibody titers fell progressively and at the last follow-up were negative ( $< 1:160$ ) in 19 patients (76 percent) in the drainage group and 17 (68 percent) in the surgery group ( $P = 0.74$ ). There were procedure-related complications in 8 patients (32 percent) in the drainage group and 21 (84 percent) in the surgery group, 17 of whom had fever postoperatively ( $P < 0.001$ ).

**Conclusions** Percutaneous drainage, combined with albendazole therapy, is an effective and safe alternative to surgery for the treatment of uncomplicated hydatid cysts of the liver and requires a shorter hospital stay. (N Engl J Med 1997;337:881-7.)

©1997, Massachusetts Medical Society.

**H**UMAN echinococcosis is a zoonotic infection caused by larval forms (metacystodes) of the tapeworm of the genus *Echinococcus* found in the small intestines of carnivores. Human infection is acquired from ingestion of the parasite eggs from infected animals.<sup>1</sup> *Echinococcus granulosus* causes cystic echinococcosis in humans, a condition that is found throughout the world and is endemic in large sheep-raising areas in Europe, Asia, the Mediterranean,

South America, and northern Kenya.<sup>2</sup> With immigration, the prevalence of the disease has increased in Europe and North America.

The most frequent site of hydatid cysts is the liver (accounting for 50 to 70 percent of cases), followed by the lungs (20 to 30 percent), and less frequently, the spleen, kidneys, heart, bones, central nervous system, and elsewhere. Cystic echinococcosis is usually asymptomatic, but a substantial number of infections cause morbidity, with occasional mortality. Hepatic hydatid cysts can rupture into the peritoneum, leading to anaphylaxis or peritoneal dissemination or both; into the biliary tract, causing cholangitis or cholestasis or both; or into the pleura or lung, causing pleural hydatidosis or bronchial fistula. Cysts may become infected and form liver abscesses. Pressure or mass effects on the bile ducts, portal veins, and hepatic veins and inferior vena cava can cause cholestasis, portal hypertension, and the Budd-Chiari syndrome, respectively.<sup>1-3</sup>

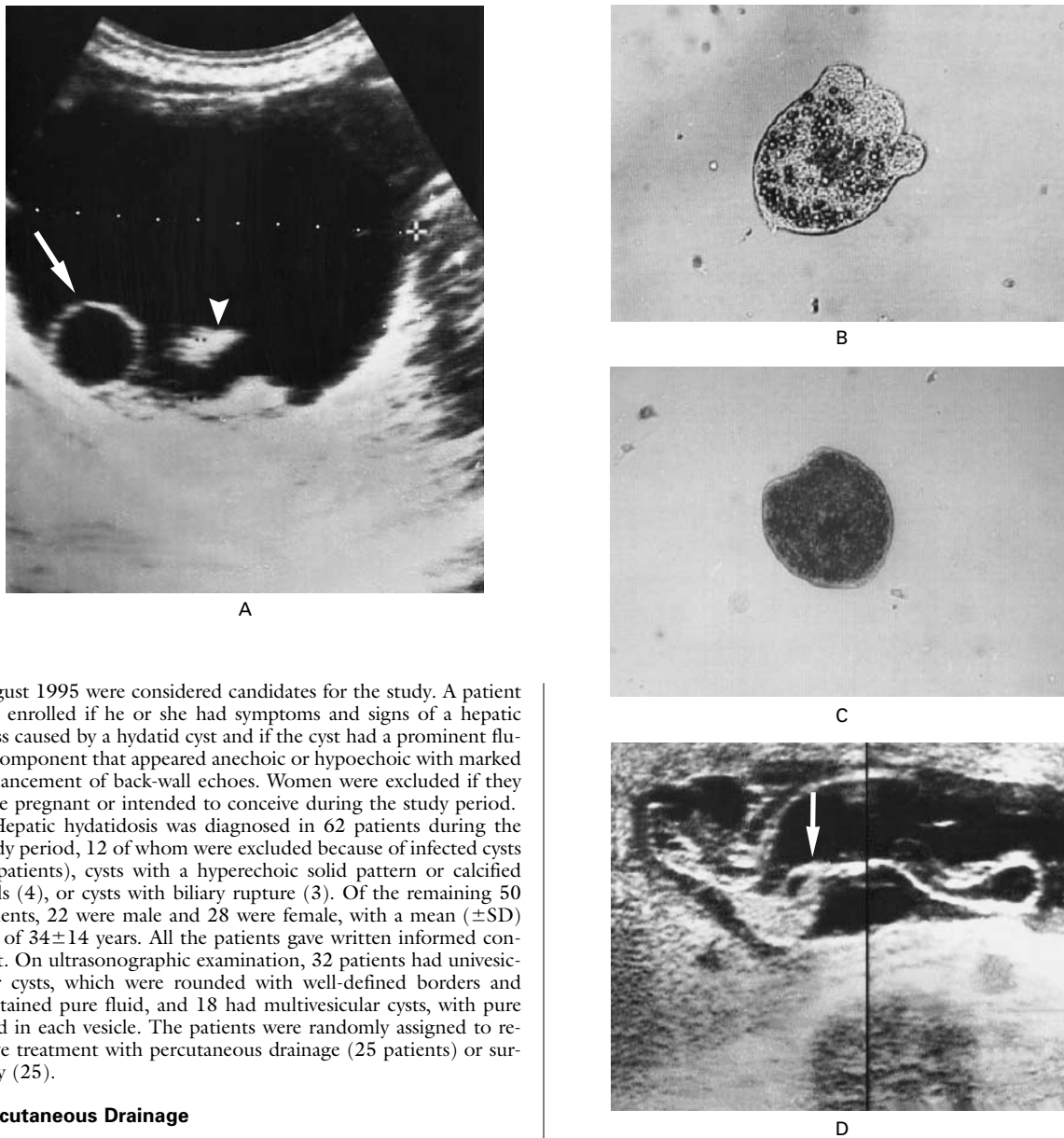
Surgery is the recommended treatment for hepatic hydatid cysts.<sup>1-3</sup> However, drug therapy and percutaneous drainage have recently been introduced as alternative treatments.<sup>2</sup> Two benzimidazoles (mebendazole and albendazole) have scolicidal activity but are clinically effective in less than 30 percent of patients with hepatic hydatidosis.<sup>4-7</sup> Percutaneous drainage is minimally invasive and very effective in the treatment of hepatic hydatidosis.<sup>8-14</sup> Studies of large numbers of patients followed for up to five years have shown that the risk of anaphylaxis is negligible, and regrowth of cysts does not occur.<sup>15-17</sup> We previously performed a prospective randomized trial of percutaneous drainage as compared with albendazole therapy in patients with hepatic hydatidosis.<sup>18</sup> We now report on a prospective randomized study of percutaneous drainage compared with surgery in 50 patients with hepatic hydatidosis.

## METHODS

**Patients**

All patients ( $\geq 14$  years of age) with hydatid cysts in the liver who presented at our institution between September 1992 and

From the Departments of Gastroenterology (M.S.K., G.J., B.A.K., G.N.Y., A.H.S., S.G.J.) and General Surgery (N.A.W.), Sheri-Kashmir Institute of Medical Sciences, Srinagar, Kashmir, India. Address reprint requests to Professor Khuroo, Section of Gastroenterology, Department of Medicine (MBC 46), King Faisal Specialist Hospital and Research Centre, P.O. Box 3354, Riyadh 11211, Saudi Arabia.



**Figure 1.** Hydatid Cyst of the Liver in a Patient Who Underwent Percutaneous Drainage.

Panel A shows a transverse ultrasonographic scan through the right hepatic lobe, demonstrating an anechoic lesion with posterior enhancement. A single daughter cyst (arrow) is attached to the posterior wall. The echogenic material at the base of the cyst (arrowhead) represents hydatid sand. The dotted line indicates the transverse diameter (7 cm) of the cyst. Panel B shows a photomicrograph ( $\times 20$ ) of aspirated cyst fluid. A single live scolex with intact hooklets can be seen. The scolex was motile on immediate microscopy. Panel C shows a photomicrograph ( $\times 20$ ) of aspirated cyst fluid after treatment with hypertonic (20 percent) saline. A single dead scolex can be seen, with loss of definition. The scolex lacked motility on immediate microscopy. Panel D shows a composite of two transverse ultrasonographic scans through the right hepatic lobe, obtained on the day after percutaneous drainage. The undulating structures (arrow) in the anechoic lesion represent separated endocyst floating in the cyst cavity.

August 1995 were considered candidates for the study. A patient was enrolled if he or she had symptoms and signs of a hepatic mass caused by a hydatid cyst and if the cyst had a prominent fluid component that appeared anechoic or hypoechoic with marked enhancement of back-wall echoes. Women were excluded if they were pregnant or intended to conceive during the study period.

Hepatic hydatidosis was diagnosed in 62 patients during the study period, 12 of whom were excluded because of infected cysts (5 patients), cysts with a hyperechoic solid pattern or calcified walls (4), or cysts with biliary rupture (3). Of the remaining 50 patients, 22 were male and 28 were female, with a mean ( $\pm$ SD) age of  $34 \pm 14$  years. All the patients gave written informed consent. On ultrasonographic examination, 32 patients had univesicular cysts, which were rounded with well-defined borders and contained pure fluid, and 18 had multivesicular cysts, with pure fluid in each vesicle. The patients were randomly assigned to receive treatment with percutaneous drainage (25 patients) or surgery (25).

#### Percutaneous Drainage

All patients undergoing percutaneous drainage were treated with albendazole, administered orally in a dose of 10 mg per kilogram of body weight per day for eight weeks.<sup>18</sup> Percutaneous drainage was performed on the 10th day of the drug regimen, under aseptic conditions, with continuous ultrasonographic guidance and close monitoring for complications, such as anaphylaxis, asthma, or laryngeal edema. The location of the cyst was defined in three planes with ultrasonography, and the relation of the cyst to the normal liver was delineated. The puncture site was selected so that the cyst could be approached through thick normal liver tissue, preferably by the intercostal route.

The procedure was performed in three steps (Fig. 1). In step 1, the cyst was punctured through the biopsy port of the puncture probe (3.5 MHz) with the use of a 5-French, 40-cm-long transhepatic catheter made of radiopaque polyethylene (Cook Europe, Bjæverskov, Denmark), and the contents were rapidly aspirated. In the patients with multivesicular cysts, a 22-gauge, 20-cm-long cholangiography needle (Cook Europe) was used to puncture and treat each daughter cyst. In step 2, the cyst cavity was nearly filled with sterile hypertonic (20 percent) saline, which was left in

the cavity for 20 minutes. In step 3, the cyst was aspirated completely, and the cavity was irrigated and left partially filled with sterile normal (0.9 percent) saline to minimize exudation or bleeding from the pericyst. During aspiration and irrigation, the separation of the endocyst from the pericyst was observed on real-time ultrasonography.

The cyst fluid was subjected to cytologic and microbiologic examination.<sup>19,20</sup> For cytologic examination, the fluid was centrifuged and the sediment examined for fragments of the laminated membrane, hooklets, and scoleces. The viability of the scoleces was assessed by observing their motility on immediate microscopy and by staining with neutral eosin. The procedure was considered successful if the reaspirated fluid revealed nonviable scoleces.

After the procedure, the patient was observed for 48 hours and then discharged from the hospital if there were no complications.

### Surgery

The surgical procedure was a simple cystectomy and drainage of the residual contents of the cyst cavity.<sup>1</sup> The abdomen was opened through a subcostal incision, and the abdominal viscera were examined, with particular attention to potential sites of dissemination, including the pelvis. The operative field was packed with swabs soaked with 10 percent povidone-iodine. The cyst was punctured and decompressed with the use of a 14-gauge needle connected to a 50-ml syringe. A sump-type cannula was introduced through the puncture site, and the cyst contents were aspirated with the use of a large-capacity reservoir and high-pressure suction. A 3-to-4-cm incision was then made at the puncture site, the cyst was opened up, and the remaining contents, including the laminated membrane, were removed with a sponge-holding forceps. The cavity of the cyst was carefully inspected for biliary communication and scrubbed with swabs soaked with povidone-iodine. Intermittent sutures were placed in the cavity of the cyst from inside, and a tube was kept in the cavity for drainage. The drain was removed on the sixth postoperative day. A cavogram was obtained before the removal of the tube in order to rule out biliary communication.

### Follow-up

At the time of enrollment, at one and three months, and subsequently every three months, the following studies were performed: a clinical examination, a urine test for albumin and sediment, blood counts, liver-function tests, kidney-function tests (measurements of serum urea and creatinine), abdominal ultrasonography, and measurement of serum echinococcal-antibody titers. The ultimate goal of treatment was the disappearance of the cyst. Other important measures of efficacy included the appearance and size of the cyst over time, the length of the hospital stay, and any complications related to the procedure. A secondary measure of efficacy was the serum echinococcal-antibody titer over time.

All ultrasonographic examinations were documented on hard copies, which were evaluated by two of us in a blinded fashion. Ultrasonography was performed with a real-time, gray-scale ultrasound unit (SSD 630, Aloka, Tokyo, Japan) and a 3.5-MHz probe. The diameter and echo pattern of the cysts were documented. In addition, the liver, biliary tree, and other abdominal organs were carefully examined for evidence of residual cysts.<sup>21,22</sup>

After percutaneous drainage or surgery, the cysts underwent a sequence of sonographic changes — namely, the appearance of high-level internal echoes (a heterogeneous pattern), obliteration by echogenic material (a pseudotumor pattern), decreased echogenicity, and finally, a normal pattern of echoes. The cyst was considered to have disappeared if it was no longer visualized on ultrasonography and the area was replaced by an ill-defined echogenic area or a normal echo pattern.

IgG antibodies to *E. granulosus* were measured by an enzyme-linked immunosorbent assay. An antibody titer higher than 1:160 was considered positive.<sup>23</sup>

The study protocol was approved by the Postgraduate Scientific

and Research Committee of the Sheri-Kashmir Institute of Medical Sciences, Srinagar, Kashmir, India.

### Statistical Analysis

Serum antibody titers were analyzed with the use of the log of the antibody values. Comparisons of discrete variables were analyzed with Fisher's exact test, and comparisons of continuous variables were analyzed with a two-sample t-test for two independent samples and a paired t-test for paired observations. In addition, we calculated the difference between group means (for continuous variables) and odds ratios (for proportions), along with 95 percent confidence intervals. Repeated-measures analysis of variance was used to compare multiple variables over time between the two groups. A Kaplan-Meier analysis was used to determine the proportion of patients in whom cysts disappeared (those with cures) on long-term follow-up, and these differences were evaluated with the log-rank test. Except where otherwise noted, all values are expressed as means  $\pm$ SD. All P values are two-sided, and a P value of less than 0.05 was considered to indicate statistical significance.<sup>24</sup>

### RESULTS

The base-line characteristics of the patients in the two groups did not differ significantly (Table 1). All the patients received the assigned treatment. Percutaneous drainage was successful in all 25 patients assigned to this treatment. Likewise, cystectomy and tube drainage were successful in all 25 patients assigned to surgery. The hospital stay was significantly shorter for the patients treated with percutaneous drainage than for those treated with surgery. After discharge from the hospital, all patients were fol-

TABLE 1. BASE-LINE CHARACTERISTICS OF THE PATIENTS IN THE TWO TREATMENT GROUPS.\*

CHARACTERISTIC	DRAINAGE GROUP (N=25)	SURGERY GROUP (N=25)
Age (yr)		
Mean	36 $\pm$ 14	33 $\pm$ 13
Range	14-60	14-65
Sex (M/F)	14/11	8/17
Mean duration of disease (yr)	2.5 $\pm$ 0.5	2.3 $\pm$ 0.5
Clinical presentation (no. of patients)		
Abdominal pain	19	20
Abdominal swelling	15	12
Enlarged liver	20	21
Mass over liver	6	5
No. of cysts	25	25
Mean diameter of cyst (cm)	8.0 $\pm$ 3.0	9.1 $\pm$ 3.0
Echo pattern (no. of cysts)		
Univesicular	16	16
Multivesicular	9	9
Location of cyst (no. of cysts)		
Right lobe	15	17
Left lobe	10	8
Serum IgG antibody titer		
$\geq$ 160 (no. of patients)	17	15
Geometric mean titer	208	208
Mean log of titer	2.32 $\pm$ 0.5	2.32 $\pm$ 0.5

\*There were no significant differences in base-line characteristics between the two treatment groups. Plus-minus values are means  $\pm$ SD.

lowed, and the mean follow-up period did not differ significantly between the two treatment groups (Table 2).

**Cyst Size**

In the drainage group, the mean diameter of the cyst was  $8.0 \pm 3.0$  cm before treatment and  $1.4 \pm 3.5$  cm at the last follow-up examination ( $P < 0.001$ ; mean difference, 7.2; 95 percent confidence interval, 5.1 to 9.4). The cyst diameter in the surgery group decreased from  $9.1 \pm 3.0$  cm before treatment to  $0.9 \pm 1.8$  cm at the last examination ( $P < 0.001$ ; mean difference, 8.6; 95 percent confidence interval, 7.1 to 10.1). The analysis of cyst diameter at follow-up excluded data from two patients in each group, who received additional treatments because of cyst infection (in one patient) or biliary rupture (in three). The cyst diameters at the last follow-up examination (Table 2) and across the 10 examinations (Fig. 2) did not differ significantly between the two treatment groups.

**Disappearance of Cysts**

In 22 patients (88 percent) in the drainage group and 18 (72 percent) in the surgery group, the cysts

disappeared ( $P = 0.29$ ; odds ratio, 2.9; 95 percent confidence interval, 0.6 to 10.6). The probability that cysts would disappear over follow-up periods in the two groups did not differ significantly ( $P = 0.5$  by the log-rank test) (Fig. 3). After percutaneous drainage, 14 univesicular cysts (88 percent) had disappeared, compared with 8 multivesicular cysts (89 percent) ( $P = 0.94$ ). Similarly, after surgery, 11 univesicular cysts (69 percent) had disappeared, as compared with 7 multivesicular cysts (78 percent) ( $P = 0.99$ ). None of the patients had an increase in the diameter of the cyst or growth of secondary vesicles in or outside the liver during follow-up.

**Serologic Studies**

Three patients (12 percent) in the drainage group and six (24 percent) in the surgery group had a fourfold rise in antibody titers in the first three months after the procedure ( $P = 0.46$ ; odds ratio, 2.3; 95 percent confidence interval, 0.5 to 8.9). The antibody titers across the 10 follow-up examinations were higher in the surgery group than in the drainage group ( $P < 0.05$  by repeated-measures analysis of variance). At the last follow-up examination, 19 patients (76 percent) in the drainage group and 17 (68

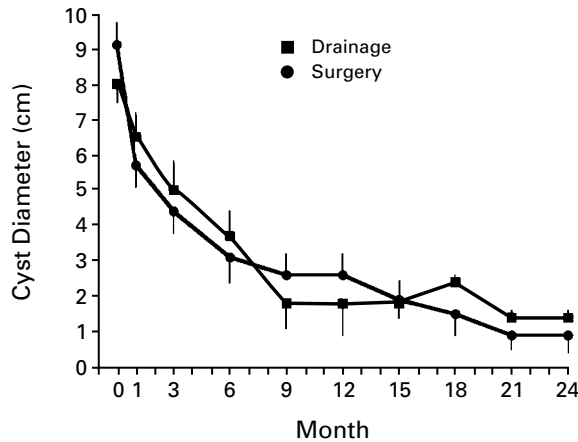
**TABLE 2. OUTCOMES AND COMPLICATIONS AFTER PERCUTANEOUS DRAINAGE OR SURGERY.\***

OUTCOME	DRAINAGE (N=25)	SURGERY (N=25)	P VALUE	MEAN DIFFERENCE (95% CI)	ODDS RATIO (95% CI)
Follow-up (mo)					
Mean	$17.5 \pm 7.0$	$17.4 \pm 6.5$	0.96	0.1	
Range	9–24	9–24		(–5.7 to 6.0)	
Hospital stay (days)					
Mean	$4.2 \pm 1.5$	$12.7 \pm 6.5$	<0.001	8.5	
Range	2–8	5–38		(5.8 to 11.2)	
Mean diameter of cyst at last visit (cm)†	$1.4 \pm 3.5$	$0.9 \pm 1.8$	0.20	0.5	
				(–1.3 to 1.7)	
Disappearance of cyst (no. of patients)	22	18	0.29		2.9 (0.6 to 10.6)
Serum IgG antibody titer (no. of patients)					
Fourfold rise in first 3 mo	3	6	0.46		2.3 (0.5 to 8.9)
<1:160	19	17	0.74		1.5 (0.4 to 4.8)
Complications (no. of patients)‡	8	21	<0.001		11.2 (2.7 to 36.0)
Early					
Hypotension	1	0			
Urticaria	2	0			
Fever	3	17			
Cyst infection	0	1			
Prolonged tube drainage	0	1			
Late					
Cyst infection	1	0			
Biliary rupture	1	2			
Incisional hernia	0	1			

\*Plus–minus values are means  $\pm$ SD. CI denotes confidence interval.

†The analysis was based on data from 23 patients in each group.

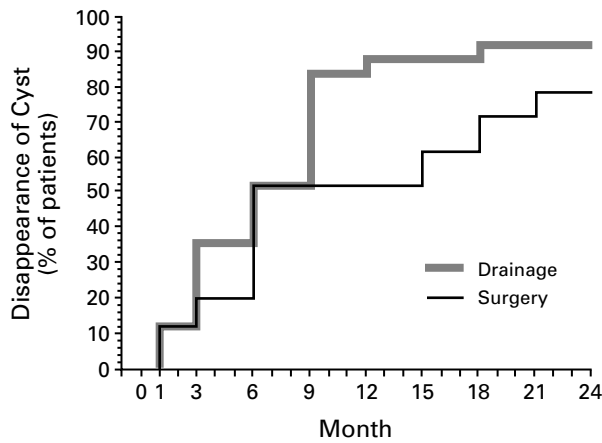
‡One patient in the drainage group and two in the surgery group underwent surgery to treat complications. One patient in the surgery group had two late complications requiring surgery (biliary rupture and incisional hernia).



No. FOLLOWED	
Drainage	25 25 25 25 25 17 17 13 12 12
Surgery	25 25 25 25 25 19 16 15 14 10

**Figure 2.** Mean (±SE) Cyst Diameter in Patients Treated with Percutaneous Drainage or Surgery.

The mean cyst diameter across the 10 examinations did not differ significantly between the two treatment groups (by repeated-measures analysis of variance).



No. AT RISK	
Drainage	25 25 22 16 12 4 4 4 3 2
Surgery	25 25 22 20 12 12 10 8 4 2

**Figure 3.** Kaplan–Meier Estimate of the Probability of the Disappearance of the Cyst (Cure) in Patients Treated with Percutaneous Drainage or Surgery (P=0.50 by the Log-Rank Test).

percent) in the surgery group had negative titers (<1:160) (P=0.74).

**Complications**

Table 2 shows the complications in the two treatment groups. After percutaneous drainage, one patient had transient hypotension, and two patients had urticaria. Three patients (12 percent) in the

drainage group and 17 (68 percent) in the surgery group had fever within 24 hours after the procedure (P<0.001; odds ratio, 15.6; 95 percent confidence interval, 3.4 to 64.7). Cultures of cyst fluid obtained from the cysts during puncture or from the drainage tube failed to document a microbial cause of fever. In all 20 patients, the fever resolved within 48 hours with symptomatic treatment. The drainage tube was removed on the sixth postoperative day from all except two patients in the surgery group. One patient required prolonged drainage, with the tube removed after three weeks. The other patient had evidence of infection in the cyst within three days after surgery, requiring reexploration and drainage of the cyst abscess. One patient in the drainage group had evidence of infection in the cyst at 18 months, requiring surgical exploration and drainage of the cyst abscess. One patient in the drainage group and two patients in the surgery group had biliary symptoms (cholangitis in two patients and cholestasis in one) at three months. Cyst–biliary communication was suspected on the basis of ultrasonographic studies and was confirmed by endoscopic retrograde cholangiopancreatography. Two patients (one in each group) were treated with endoscopic sphincterotomy and basketing of the contents of the ruptured cyst, and the third patient (in the surgery group) underwent reexploration, drainage of the bile duct, and a repair of the incisional hernia. There were no procedure-related deaths in either group.

**DISCUSSION**

In our study, the surgical treatment for managing hydatid cysts in the liver was simple cystectomy.<sup>25</sup> We first used the technique of percutaneous drainage of hydatid cysts in 1988, and we used this approach in 75 patients before performing the current study.<sup>10</sup> Patients treated with percutaneous drainage received albendazole therapy on the basis of data from our previous randomized, prospective study of drainage versus albendazole therapy.<sup>18</sup> Since there are no published data on the merits of albendazole therapy in patients undergoing surgery for hepatic hydatidosis, the drug was not used in the patients in the surgery group. We believe that the use of different scolical agents in the two treatment groups did not influence the results of the study. Our aim was not to compare the efficacy of different scolical agents but instead to compare the therapeutic effects of a new procedure with those of standard surgical treatment.<sup>26-29</sup> During surgery, we did not inject the scolical agent into an intact cyst but instead swabbed the residual cyst cavity with povidone–iodine, after the laminated membrane and daughter cysts had been removed.<sup>26</sup> The instillation of scolical agents into the cyst cavity at surgery has been associated with severe systemic or biliary com-

plications, possibly caused by breaks in the laminated membrane and contact between the scolical agent and liver tissue around the cyst, with eventual systemic absorption or biliary spillage.<sup>30,31</sup> In fact, most investigators who have extensive experience with the surgical treatment of hepatic hydatidosis do not instill scolical agents in the cyst cavity. During percutaneous drainage, the scolical agent is instilled in the cyst cavity through a needle puncture under ultrasonographic guidance, and the instilled fluid does not come into contact with the pericyst. Systemic absorption or biliary spillage is thus avoided. We have not observed any systemic or biliary complications related to the instillation of the scolical agent in the cyst cavity during percutaneous drainage.

The final diameter of the cyst and its disappearance on follow-up (overall and across the 10 examinations) did not differ significantly between the two treatment groups. After percutaneous drainage, the cyst was filled with nonviable remnants of the scoleces, daughter cysts, and laminated membrane, resulting in the obliteration of the cyst cavity. In contrast, at surgery all the contents of the cyst were removed, leaving a cavity that was subsequently filled by the exudate from the pericyst. It is generally believed that drainage is indicated only for univesicular cysts, and the procedure may be technically difficult in the case of multivesicular cysts. However, data from this study and our earlier studies show that percutaneous drainage is effective for both univesicular and multivesicular cysts.<sup>10,18</sup>

After both percutaneous drainage and surgery, the titer of antibodies to *E. granulosus* rose, possibly because of spillage and systemic absorption of the contents of the cyst. A rise in the antibody titer was more frequent and higher in the surgery group than in the drainage group, suggesting that there was more spillage of the cyst contents after surgery.

The complications were similar in the two groups. Fever after either procedure may have resulted from a reaction to the absorbed scolical agent or cyst contents or from aseptic inflammation of the cyst cavity.<sup>10,18</sup> The significantly higher percentage of patients with fever after surgery was presumably due to systemic absorption of larger quantities of the scolical agent or hydatid contents or both during surgery than during percutaneous drainage. The abscess in one patient in the postoperative period was caused by ineffective cyst drainage. However, the delayed development of an abscess in another patient after percutaneous drainage was presumably related to delayed resolution, with residual dead cyst contents forming a focus for bacterial infection. Cyst-biliary communication after percutaneous drainage or surgery is caused by decompression of the cyst and can be managed endoscopically.<sup>10,18,32</sup> One patient in the drainage group had short-lasting hy-

potension, and two patients in the drainage group had urticaria. Although serious allergic manifestations after the puncture of a cyst are reported to be rare, one of our patients may have had anaphylaxis. This possibility makes close monitoring mandatory during percutaneous drainage, with facilities available for treating potential complications, especially anaphylaxis and laryngeal edema.<sup>10,17,18</sup>

Percutaneous drainage of uncomplicated hepatic hydatid cysts can be performed safely and results in the disappearance of the cyst. The efficacy of percutaneous drainage is similar to that of standard treatment with cystectomy, in terms of reducing the size of the cyst and causing its disappearance over a period of up to two years. The advantages of percutaneous drainage include a shorter hospital stay and a lower complication rate.

## REFERENCES

- Milicevic M. Hydatid disease. In: Blumgart LH, ed. Surgery of the liver and biliary tract. 2nd ed. Vol. 2. Edinburgh, Scotland: Churchill Livingstone, 1994:1121-50.
- Ammann RW, Eckert J. Cestodes: Echinococcus. Gastroenterol Clin North Am 1996;25:655-89.
- WHO Informal Working Group on Echinococcosis. Guidelines for treatment of cystic and alveolar echinococcosis in humans. Bull World Health Organ 1996;74:231-42.
- Gil-Grande LA, Boixeda D, Garcia-Hoz F, et al. Treatment of liver hydatid disease with mebendazole: a prospective study of thirteen cases. Am J Gastroenterol 1983;78:584-8.
- Morris DL, Dykes PW, Marriner S, et al. Albendazole — objective evidence of response in human hydatid disease. JAMA 1985;253:2053-7.
- Teggi A, Lastilla MG, De Rosa F. Therapy of human hydatid disease with mebendazole and albendazole. Antimicrob Agents Chemother 1993;37:1679-84.
- Gil-Grande LA, Rodriguez-Caabeiro F, Prieto JG, et al. Randomised controlled trial of efficacy of albendazole in intra-abdominal hydatid disease. Lancet 1993;342:1269-72.
- Filice C, Pirola F, Brunetti E, Dughetti S, Strosselli M, Foglieni CS. A new therapeutic approach for hydatid liver cysts: aspiration and alcohol injection under sonographic guidance. Gastroenterology 1990;98:1366-8.
- Gargouri M, Ben Amor N, Ben Chehida F, et al. Percutaneous treatment of hydatid cysts (*Echinococcus granulosus*). Cardiovasc Intervent Radiol 1990;13:169-73.
- Khuroo MS, Zargar SA, Mahajan R. Echinococcus granulosus cysts in the liver: management with percutaneous drainage. Radiology 1991;180:141-5.
- Acunas B, Rozanes I, Celik L, et al. Purely cystic hydatid disease of the liver: treatment with percutaneous aspiration and injection of hypertonic saline. Radiology 1992;182:541-3.
- Giorgio A, Tarantino L, Francica G, et al. Unilocular hydatid liver cysts: treatment with US-guided, double percutaneous aspiration and alcohol injection. Radiology 1992;184:705-10.
- Simonetti G, Profili S, Sergiacomi GL, Meloni GB, Oracchio A. Percutaneous treatment of hepatic cysts by aspiration and sclerotherapy. Cardiovasc Intervent Radiol 1993;16:81-4.
- Bastid C, Azar C, Doyer M, Sahel J. Percutaneous treatment of hydatid cysts under sonographic guidance. Dig Dis Sci 1994;39:1576-80.
- Akhan O, Ozmen MN, Dincer A, Sayek IS, Gocmen A. Liver hydatid disease: long-term results of percutaneous treatment. Radiology 1996;198:259-64.
- Schiller CF. Complications of echinococcus cyst rupture: a study of 30 cases. JAMA 1966;195:220-2.
- Placer C, Bordas JM, Frias FJ, Sacristan B. The management of hydatid liver cysts with aspiration and alcohol. Gastroenterology 1991;100:290.
- Khuroo MS, Dar MY, Yattoo GN, et al. Percutaneous drainage versus albendazole therapy in hepatic hydatidosis: a prospective, randomized study. Gastroenterology 1993;104:1452-9.
- Smyth JD, Barrett NJ. Procedures for testing the viability of human hydatid cysts following surgical removal, especially after chemotherapy. Trans R Soc Trop Med Hyg 1980;74:649-52.
- Gori S, Campatelli A, Luchi S, Paladini A, Savalli E, Scasso A. Cytol-

ogy in the percutaneous treatment of hydatid cysts: a report of four cases. *Acta Cytol* 1993;37:423-6.

21. Zargar SA, Khuroo MS, Khan BA, Dar MY, Alai MS, Koul P. Intrahepatic rupture of hepatic hydatid cyst: sonographic and cholangiographic appearances. *Gastrointest Radiol* 1992;17:41-5.
22. Yalin R, Aktar AO, Acikgozoglul S. Computed tomography and sonography of hydatid cysts of the liver after surgical treatment. *J Med Imaging* 1989;3:301-5.
23. Wattal C, Malla N, Khan IA, Agarwal SC. Comparative evaluation of enzyme-linked immunosorbent assay for the diagnosis of pulmonary echinococcosis. *J Clin Microbiol* 1986;24:41-6.
24. Munro BH, Visintainer MA, Page EB. *Statistical methods for health care workers*. Philadelphia: J.B. Lippincott, 1986.
25. Morris DL. Echinococcus of the liver. *Gut* 1994;35:1517-8.
26. Ekrami Y. Surgical treatment of hydatid disease of the liver. *Arch Surg* 1976;111:1350-2.
27. Langer JC, Rose DB, Keystone JS, Taylor BR, Langer B. Diagnosis and

management of hydatid disease of the liver: a 15-year North American experience. *Ann Surg* 1984;199:412-7.

28. Sayek I, Yalin R, Sanac Y. Surgical treatment of hydatid disease of the liver. *Arch Surg* 1980;115:847-50.
29. Karavias DD, Vagianos CE, Bouboulis N, Rathosis S, Androulakis J. Improved techniques in the surgical treatment of hepatic hydatidosis. *Surg Gynecol Obstet* 1992;174:176-80.
30. Castellano G, Moreno-Sanchez D, Gutierrez J, Moreno-Gonzalez E, Colina F, Solis-Herruzo JA. Caustic sclerosing cholangitis: report of four cases and a cumulative review of the literature. *Hepatogastroenterology* 1994;41:458-70.
31. Tsimoyiannis EC, Grantzis E, Moutesidou K, Lekkas ET. Secondary sclerosing cholangitis: after injection of formaldehyde into hydatid cysts in the liver. *Eur J Surg* 1995;161:299-300.
32. al Karawi MA, Yasawy MI, el Shiekh Mohamed AR. Endoscopic management of biliary hydatid disease: report on six cases. *Endoscopy* 1991; 23:278-81.